

Inhalation of Baby Powder

Talc is harmless if it is ingested or applied topically, yet the consequences can be severe—and even deadly if it is inhaled. In this case, a child presents emergently with a diffuse bronchiolar inflammatory reaction after acute talcum powder inhalation.

Fiona M. Garlich, MD, and Lewis S. Nelson, MD

Case

A previously healthy 11-month-old boy is brought by his mother to the ED approximately 20 minutes after he inhaled baby powder during a diaper change. The mother states that immediately after the exposure, the infant had an episode of coughing in which he “turned blue,” but then he rapidly improved. Upon arrival to the ED, he is noted to be tachypneic, with a respiratory rate of 40 to 60 breaths/min. His oxygen saturation is 98% on room air, and his vital signs include a blood pressure of 90/55 mm Hg; heart rate, 104 beats/min; and temperature, 37.1 °C. Findings on a chest radiograph are unremarkable. In the ED, the patient receives empiric prednisone and is admitted for overnight observation in the pediatric ward. He is discharged well the next day.

One day later, the patient returns to the ED with grunt-ing respirations, subcostal retractions, diffuse crackles, a respiratory rate of 60 breaths/min, oxygen saturation of 92%, and a temperature of 39.4 °C. His white blood cell count is 20,000 cells/ μ L. Arterial blood gas analysis reveals a pH of 7.4; PCO_2 , 32 mm Hg; and PO_2 , 85 mm Hg. A repeat chest radiograph (Figure 1) demonstrates increased bronchovascular markings and hyperinflation, suggesting a diffuse bronchiolar inflammatory reaction. No focal infiltrates are seen. Upon the treating physician's

request, the parents bring in the container of baby powder. It contains talc, at a concentration of 81%.

What is talc?

Talc is hydrated magnesium silicate ($Mg_3Si_4O_{10}(OH)_2$), a pearly white, naturally occurring mineral found geologically in deposits around the world. It is the softest mineral on earth, and its name is derived from the Arabic *talq*, meaning “pure.” Talc has been used for millennia and is currently included in a myriad of industrial and consumer products, including plastic, paint, cosmetics, lubricants, pharmaceuticals, gymnastic chalk, decorative soapstone, and talcum powder or baby powder. Talcum powder, which consists of finely ground talc, has soothing, lubricating, and absorptive properties when applied to the skin. Because of these attributes, talcum powder was introduced in 1893 for use as baby powder. Paradoxically, talc is used medically as a pleurodesis agent to prevent recurrent pneumothorax, due to its ability to incite a localized inflammatory reaction when applied to the pleural surfaces.

What are the symptoms and complications of acute talc inhalation?

While ingestion or topical application of talc produces a benign effect, the substance acts as an irritant when it is inhaled.¹ Findings can range from cough, sneezing, and transient dyspnea to cyanosis, severe respiratory distress, respiratory failure, and even death.^{1,2} Many cases of symptomatic talc inhalation have been reported, primarily in infants and preschool-aged children.³ Most inhalation incidents occur at the time of a diaper change, but such events have also occurred when the child accidentally inverted the talcum powder container or when older children were mimicking the use of powder on a

Dr. Garlich is a fellow in medical toxicology in the department of emergency medicine at the New York University School of Medicine in New York City and the New York City Poison Control Center. **Dr. Nelson** is an associate professor in the department of emergency medicine and director of the medical toxicology fellowship program at the New York University School of Medicine and the New York City Poison Control Center. He is also a member of the EMERGENCY MEDICINE editorial board.

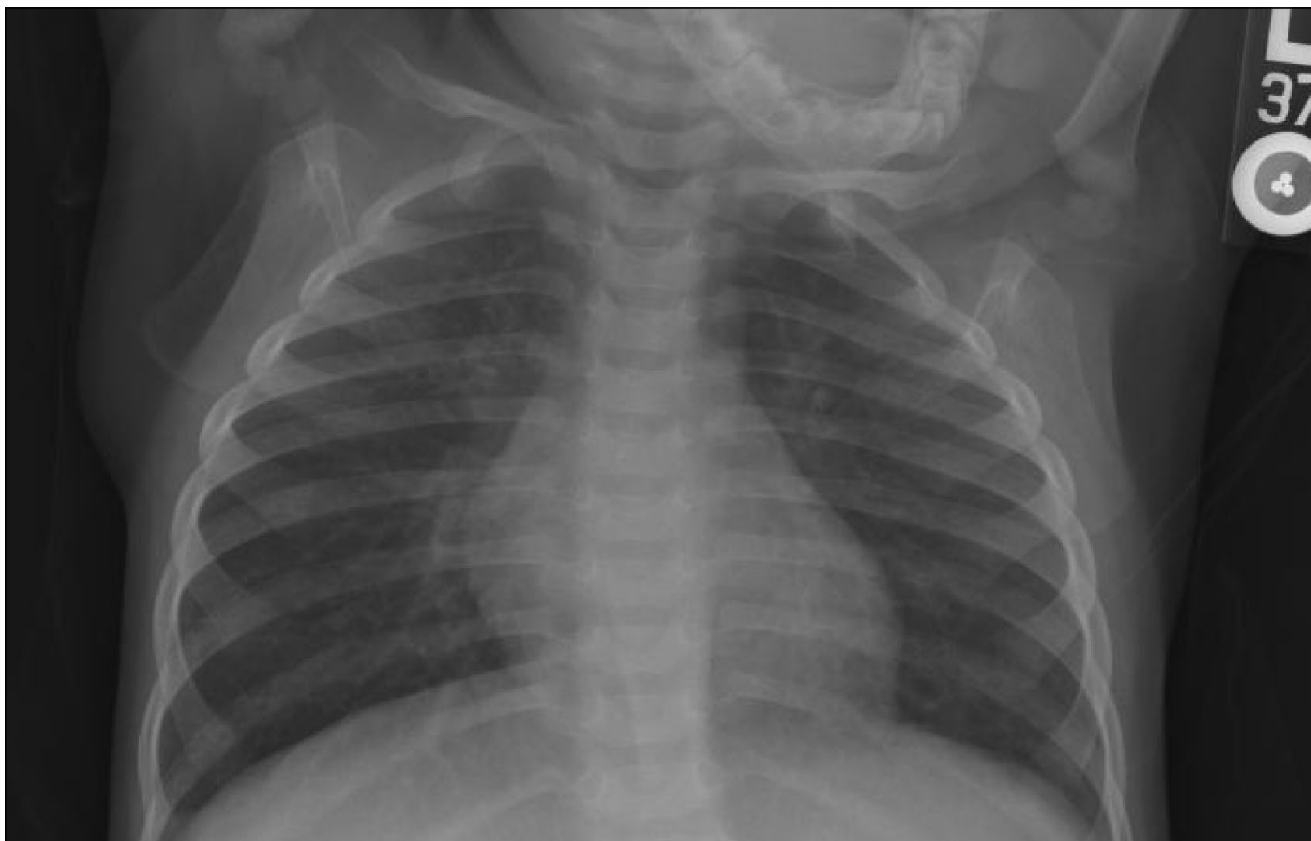


FIGURE 1. Repeat chest radiograph showing hyperinflation and increased bronchovascular markings, evidence of a diffuse bronchiolar inflammatory reaction.

younger sibling.³ The onset of consequential symptoms is often delayed several hours from the time of inhalation,¹ as in the case of our patient, but may occur more rapidly following massive inhalational exposure. Subsequently, pneumonitis, bronchiolitis, diffuse pulmonary infiltrates, acute lung injury, bronchiolar obstruction, or pneumonia from bacterial superinfection can occur, leading to severe pulmonary compromise, including acute respiratory distress syndrome. The reported mortality in severe talc pulmonary toxicity ranges from 20% to 33% in case series.^{1,4}

What is the pathophysiology of pulmonary injury in acute talc inhalation?

Talc is insoluble in water, causing drying of the mucous membranes of the tracheobronchial tree when it is inhaled. This results in impairment of the normal ciliary function that is required to clear particulate matter from the airways.¹ Edema and inflammation of the bronchial epithelium occur, leading to a pattern typical of acute lung injury. Inhalation of talcum powder can also cause

mechanical obstruction of the small airways.² Mice that inhaled talcum powder were found on autopsy to have bronchioles obstructed with talc, and histologic examination of the bronchial epithelium revealed hemorrhage, edema, and desquamation.² Furthermore, adsorption of surfactant to the magnesium silicate powder may contribute to pulmonary injury.^{1,2}

What therapeutic options exist for the treatment of acute pulmonary injury caused by talc inhalation?

The primary goal in the treatment of patients with acute talcum powder inhalation is to maintain adequate ventilation and oxygenation. Supplementary oxygen should be administered as needed; intubation and mechanical ventilation may be required. A trial of inhaled bronchodilators is reasonable as appropriate, although data to support their use have not been reported. Corticosteroids, either oral or parenteral, are frequently administered in an attempt to mitigate the local inflammatory response. While the benefits of steroids have not been confirmed in clinical

trials, there was a trend towards mortality benefit in a retrospective review.⁴ Generally accepted regimens include methylprednisolone 0.5 to 1 mg/kg IV every 6 hours, or prednisone/prednisolone 1 to 2 mg/kg/day orally, both for a total of 3 to 5 days. Bronchoalveolar lavage may be beneficial in the setting of massive talc inhalation, but its use has only been anecdotally reported.^{1,4}

Is talc still used in baby powder?

Many parenting guides recommend against the use of talcum powder for infants. Cornstarch-based baby powder—which is noninflammatory and associated with substantially lower risk if inhaled—was introduced in response to public awareness of the dangers of lung injury from talcum powder. However, talc-containing products are still readily available at many retail locations. They are often labeled simply as “baby powder” and are found side-by-side with cornstarch-based diaper powder in the baby care aisle (Figure 2). Some talcum powder containers have warnings cautioning against the dangers of inhalation, but many do not. The labeling of these products may be unclear or easily overlooked, leading to the interchangeable use of talcum and cornstarch powders. Though the incidence of talcum powder inhalation has decreased, it still poses a significant public health risk. The American Association of Poison Control Centers reported that in



FIGURE 2. Baby powders containing talc are often labeled simply as “baby powder” (left). In many stores, they can be found on the same shelf with cornstarch-containing powders (right).

2008 there were 2,526 exposures to powders made of talc; 87% of these occurred in children younger than 6 years.⁵

Besides acute inhalation, what other causes of talc-related pulmonary toxicity exist?

The chronic inhalation of talc dust has long been associated with chronic pulmonary disease in talc miners and

industrial workers. Chronic inhalation of talc dust in the industrial setting can lead to talcosis, a condition characterized by chronic bronchitis, interstitial fibrosis, and/or granuloma formation.¹ Naturally occurring talc often contains contaminating minerals such as crystalline silica and tremolite asbestos, which can lead to pulmonary damage in miners who are exposed to it. The resulting conditions, termed talcosilicosis and talcoasbestosis, are clinically and radiographically similar to silicosis and asbestosis, respectively.

Pulmonary toxicity resulting from the IV injection of talc-containing xenobiotics has also been described in the medical literature.^{1,6} One means of drug abuse involves crushing, solubilizing, and filtering oral medications and injecting them intravenously. Talc is a common component of many tablet formulations and thus can be inadvertently injected if the filtering step is inadequate. The talc crystals are retained in the pulmonary capillary bed and produce angiothrombosis, granulomas, and interstitial fibrosis, which may lead to pulmonary hypertension and cor pulmonale.^{1,6}

Case Conclusion

The patient was treated with IV methylprednisolone, along with ceftriaxone as empiric coverage for possible bacterial pneumonia. He was admitted to the pediatric ICU, where he improved clinically during the next 2 days. Intubation and advanced ventilatory support were not required, and the patient was discharged on hospital day 3 to complete a 5-day course of oral prednisolone. **EM**

References

1. Hollinger MA. Pulmonary toxicity of inhaled and intravenous talc. *Toxicol Lett.* 1990;52(2):121-127.
2. Motomatsu K, Adachi H, Uno T. Two infant deaths after inhaling baby powder. *Chest.* 1979;75(4):448-450.
3. Pairaudeau PW, Wilson RG, Hall MA, Milne M. Inhalation of baby powder: an unappreciated hazard. *BMJ.* 1991;302(6786):1200-1201.
4. Brouillette F, Weber ML. Massive aspiration of talcum powder by an infant. *Can Med Assoc J.* 1978;119(4):354-355.
5. Bronstein AC, Spyker DA, Cantilena LR Jr, et al. 2008 Annual Report of the American Association of Poison Control Centers' National Poison Data System (NPDS): 26th Annual Report. *Clin Toxicol.* 2009;47(10):911-1084.
6. Arnett EN, Battle WE, Russo JV, Roberts WC. Intravenous injection of talc-containing drugs intended for oral use. A cause of pulmonary granulomatosis and pulmonary hypertension. *Am J Med.* 1976;60(5):711-718.